



## Closed Spontaneous Rupture of the Flexor Tendon in Zone 3: A Case Series

Navapong Thitiworakarn, MD, Chaiyos Vinitpairot, MD, Surut Jianmongkol, MD

*Department of Orthopedics, Faculty of Medicine, Khon Kaen University, Khon Kaen, Thailand*

**Purpose:** The pathophysiology of spontaneous rupture is not fully understood. Spontaneous rupture has been questioned, as some authors have stated that most spontaneous ruptures cannot be attributed to a cause or have not yet been investigated. Zone 3 was the most common place for flexor tendon ruptures to happen on their own, but the risk factor was not found.

**Methods:** From 2019 to 2022, we recorded four cases of closed rupture of the flexor tendon in zone 3 caused by agricultural activity. The history of all patients such as steroid injections, pain, and underlying conditions, was reviewed. Some parts of the tendon, debrided from the injury site, were sent for pathologic examination. The final range of motion and activity were recorded.

**Results:** All our patients had acute symptoms while gripping tools and excavating dirt during gardening. All flexor tendon ruptures occurred in zone 3, and were repaired by core and epitendinous suture. There was no actual condition believed to be the cause of the rupture. All patients achieved nearly full range of motion in the final follow-up.

**Conclusions:** A firm grip while performing agricultural tasks appears to be a risk factor of closed rupture flexor tendon. Although it is uncommon for a closed rupture of a flexor tendon injury to occur without ascertainable causes, this condition should be recognized while facing weakness or an inability to flex the finger.

**Keywords:** spontaneous rupture, closed rupture, flexor tendon, agricultural task

Boyes et al. recorded the first spontaneous flexor tendon rupture of the hand; however, its pathophysiology remains unknown<sup>(1)</sup>. Although closed rupture of the flexor tendon in zone 3 is uncommon, a spontaneous rupture in this location has been observed to be more common than in the other zones<sup>(2)</sup>. However, the weakest zone of the flexor tendon is zone 1, and typically, closed

damage occurs in footballers or athletes<sup>(3)</sup>. The cause of non-traumatic closed flexor tendon rupture is unknown but is considered, by some authors, to be misdiagnosed as spontaneous rupture<sup>(4)</sup>. Attrition of the tendon to the osteophyte or nonunion carpal bone, gouty infiltration, aberrant bifurcation of the tendon, or abnormal insertion of lumbrical muscle are all possible etiologies.

From 2019 to 2022, we documented four occurrences of acute closed ruptured flexor tendons in zone 3 caused by a firm grip during agricultural activities. Four patients developed acute symptoms while gripping tools and excavating the ground while gardening, whereas one patient experienced no symptoms. This study was approved by our

*Article history:*

*Received: January 6, 2022 Revised: March 31, 2022*

*Accepted: May 9, 2022*

*Correspondence to: Chaiyos Vinitpairot, MD*

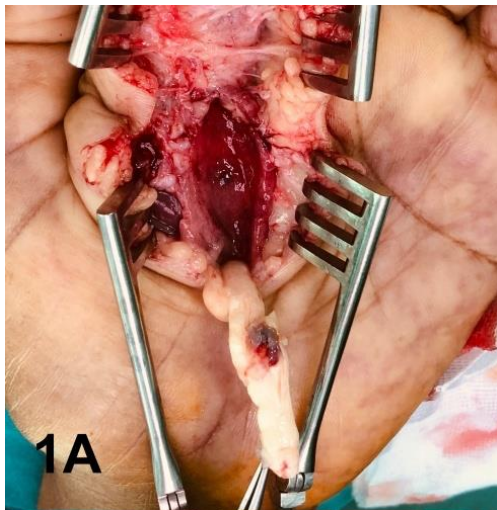
*Department of Orthopedics, Faculty of Medicine, Khon Kaen University, Khon Kaen, Thailand*

*E-mail: [chaiyi@kku.ac.th](mailto:chaiyi@kku.ac.th)*

institutional review board, and informed consents for the publication were obtained from all patient.

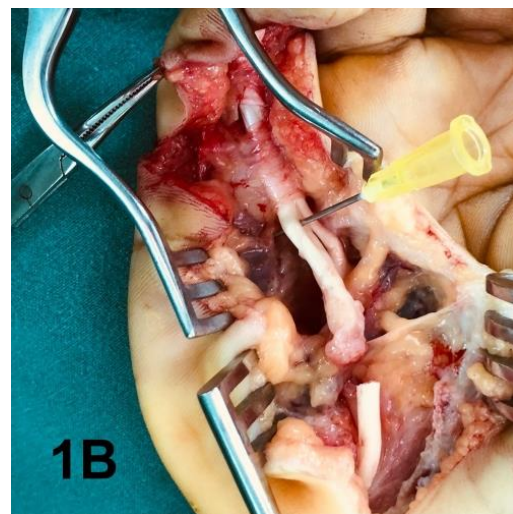### CASES SERIES

**Case 1:** A 65-year-old man was unable to flex his left index finger for one month. While clutching a sickle, he experienced a painful snapping sensation at the base of his left index finger. The patient was unable to flex his left index. Physical examination revealed a ruptured flexor tendon; he could not actively flex his left index finger at both the proximal interphalangeal (PIP) and distal interphalangeal (DIP) joints. As shown in [Figure 1A](#), intraoperative examination revealed a complete tear of the flexor digitorum profundus (FDP) and flexor digitorum superficialis (FDS) at zone 3 of the left index finger. There was no evidence of infection or chronic inflammatory synovial tissue in the ruptured area. The distal stumps of the FDS and FDP tendons are proximal to the A1 pulley of the left index finger. However, the proximal stumps of both tendons retracted to the distal border of the carpal tunnel. The FDS was used as a tendon graft to repair the FDP tendon using the modified Kessler core 4-strand suture technique.



**Fig. 1A.** Operative Finding of Case 1. The complete tear of FDP and FDS was found in zone 3 of the left index. There was no sign of infection or other chronic inflammatory synovial tissue around the rupture site.

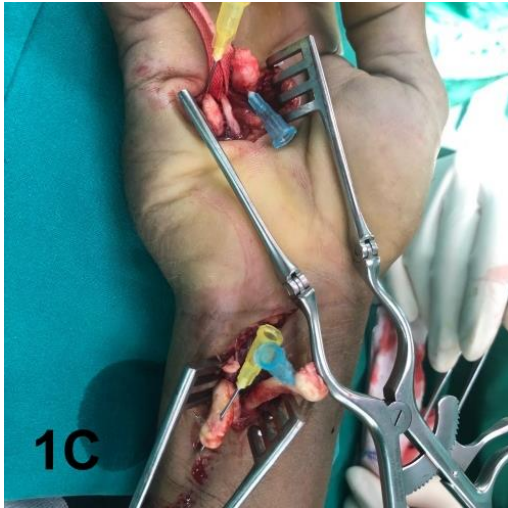
**Case 2:** A 45-year-old woman was unable to flex her right little finger for two months. She felt a “snap” sensation in her right hand when she was grasping the shovel. Her physical examination revealed that she was unable to flex her right little finger's PIP and DIP joints actively. A complete tear of FDP and FDS were discovered in zone 3 right little finger as demonstrated in [Figure 1B](#). The distal stump of tendons was located at distal to the lumbrical attachment. The FDP tendon was repaired using a modified Kessler approach supplemented with epitendinous sutures.



**Fig. 1B.** Operative Findings in Case 2. The distal stump of tendons was found at the distal to the lumbrical attachment.

**Case 3:** A 56-year-old man lost the ability to flex his right little finger for five weeks while digging. During the physical examination, a palpable, painless, hard, moveable mass was discovered on his right wrist. In this case, the patient had a history of gout; however, histological examination of the tissue revealed no evidence of gout. Due to the palpable mass in the wrist area, we made two different incisions: a longitudinal incision in the palmar area and a curved incision on the ulnar side of the right wrist. As shown in [Figure 1C](#), a complete tear of the FDP and FDS was discovered in Zone 3 of the right little finger. Between the A1 pulley and the carpal tunnel, the proximal and distal stumps of the tendons were

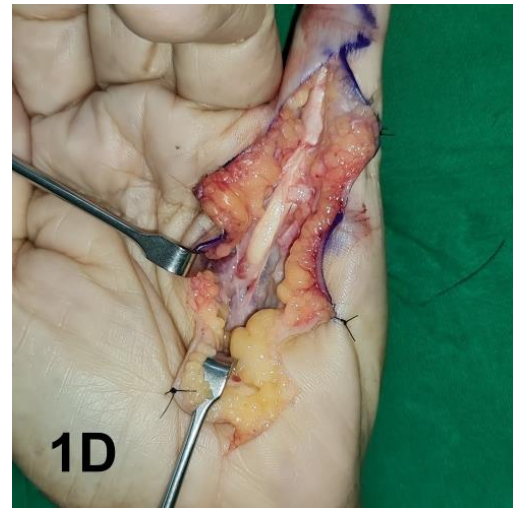
discovered just proximal to the distal wrist crease and distal to the distal carpal tunnel border, respectively. The FDP and FDS tendons were entirely repaired, using a modified Kessler approach supplemented with epitendinous sutures.



**Fig. 1C.** Operative finding of Case 3. At the wrist, the proximal stump of the ruptured tendon was discovered. The distal stump was located between the A1 pulley and the distal end of the carpal tunnel.

**Case 4:** A 79-year-old man who could not bend his left little finger presented to our hospital. He felt a snap in his palm one week before coming to the hospital while digging the earth with a hoe. He felt pain in his palm and could not flex his little finger. He has a history of hypertension. In zone 3, a complete tear of the FDP was observed, as demonstrated in [Figure 1D](#). The FDS of the small finger was missing, and the proximal stump of the FDP was retracted into the carpal tunnel. However,

an FDP tendon can be repaired primarily using a 4-strand core suture. No bony spur or bone disease was observed at the injury site.



**Fig. 1D.** Operative finding of Case 4. A distal stump of the FDP was discovered near the A1 pulley, while a proximal stump was discovered near the carpal tunnel. The little finger's FDS was absent.

None of the patients had a history of hand trauma, steroid injections, or open wounds. Pathological examination revealed no evidence of inflammation due to gout, and culture revealed no growth of bacteria or tuberculosis. All patients underwent exploratory surgery and tenorrhaphy with or without tendon grafting. A conventional Brunner incision was made. Proximally, bone and infiltrative lesions were considered possible explanations, but no pathology was discovered. At the latest follow-up, all patients reached nearly full motion and returned to normal activity levels. The case series are summarized in [Table 1](#).

**Table 1** The summary of the case series (n=4).

Case	Gender	Age	Etiology	Presentation	Digit (Zone)	Management
1	Male	65	Strong grip while grasping the sickle	Snapping in palm	Index finger (Zone 3)	Tendon grafting
2	Female	45	Strong grip while grasping a shovel	Snapping in palm	Little finger (Zone 3)	Direct repair
3	Male	56	Strong grip while digging	Palpable mass, unable to flex the finger	Little finger (Zone 3)	Direct repair
4	Male	79	Strong grip while digging with a hoe	Snapping in palm	Little finger (Zone 3)	Direct repair

## DISCUSSION

Nontraumatic closed rupture of the flexor tendons are infrequent. There could be numerous causes. They typically occur at the tendon-bone junction in zone 1 due to the junction's weak location and the strongest section being the musculotendinous junction<sup>(5)</sup>. However, closed flexor tendon ruptures in zone 3 are prevalent among spontaneous flexor tendon ruptures<sup>(6,7)</sup>. It was noted that ruptures most frequently occur during moments of peak tendon strain but can also occur in the absence of recognizable trauma<sup>(1)</sup>. Lee and McGrouther, on the other hand, conducted a study of the literature and determined that these previous case reports may have been mislabeled<sup>(4)</sup>. The authors speculated that there might be a dearth of documentation of proximal zone pathology. Nonetheless, three plausible explanations for the closed flexor tendon rupture in zone 3 were identified. First, the bifurcation of FDP tendons side-to-side may be a weak area due to shearing stress<sup>(7-9)</sup>. Second, an aberrant lumbrical muscle insertion could create strain between the tendon and the immobile lumbrical muscle insertion<sup>(7)</sup>. Ischemia is a final possibility, as there was a watershed area between the tendon and lumbrical muscle<sup>(10)</sup>.

We present four cases of acute closed rupture of the flexor tendon in zone 3 caused by agricultural activity. All our patients had acute symptoms while firmly grasping tools and excavating the ground during gardening. None of the patients had a history of hand trauma or fracture, and there was no evidence of underlying disease or anatomy variance of the tendon as a likely cause<sup>(9)</sup>. All rupture sites in this series were within zone 3; however, the distal ends of the tendons were at varying levels, causing patients to experience a "pop" or "snap" sensation and pain. Closed tendon rupture could be confused with other causes, such as weakness from nerve palsy if the patient never experiences a pop or snap sensation. Tenodesis and sensation examination help differentiate between tendon and nerve pathologies. Preoperative imaging, such as MRI or ultrasound, can provide information about possible causes, tendon gap, and tendon stump. In this report, only case 4 underwent

preoperative ultrasound, which reported a severed tendon and no mass.

## CONCLUSION

Our report emphasizes the possibility of a non-traumatic flexor tendon rupture associated with vigorous grasping during agricultural work. The pathophysiology of this nontraumatic closed rupture of the flexor tendon warrants additional investigation, as does its spontaneous occurrence.

## REFERENCES

1. Boyes JH, Wilson JN, Smith JW. Flexor-tendon ruptures in the forearm and hand. *J Bone Joint Surg Am* 1960;42-A:637-46.
2. Patel AP, Wong KY. Spontaneous flexor tendon rupture in the palm. *BMJ Case Rep* 2015;2015:bcr2014208141.
3. Ostric SA, Russell RC, Petrungraro J. Closed zone III rupture of the flexor digitorum profundus tendons of the right index, long, and ring fingers in a bowler: Gutterball syndrome. *Hand (N Y)* 2010;5:378-81.
4. Lee JS, McGrouther DA. Are flexor tendon ruptures ever spontaneous? - A literature review on closed flexor tendon ruptures of the little finger. *J Hand Surg Asian Pac Vol* 2019;24:180-8.
5. Benjamin M, Toumi H, Ralphs JR, et al. Where tendons and ligaments meet bone: attachment sites ('entheses') in relation to exercise and/or mechanical load. *J Anat* 2006;208:471-90.
6. Netscher DT, Badal JJ. Closed flexor tendon ruptures. *J Hand Surg Am* 2014;39:2315-23.
7. Bois AJ, Johnston G, Classen D. Spontaneous flexor tendon ruptures of the hand: case series and review of the literature. *J Hand Surg Am* 2007;32:1061-71.
8. Masaki F, Isao T, Aya Y, Ryuuji I, Yohjiroh M. Spontaneous flexor tendon rupture of the flexor digitorum profundus secondary to an anatomic variant. *J Hand Surg Am* 2007;32:1195-9.

9. Davis C, Armstrong J. Spontaneous flexor tendon rupture in the palm: the role of a variation of tendon anatomy. *J Hand Surg Am* 2003;28:149-52.
10. Manske PR, Lesker PA. Flexor tendon nutrition. *Hand Clin* 1985;1:13-24.